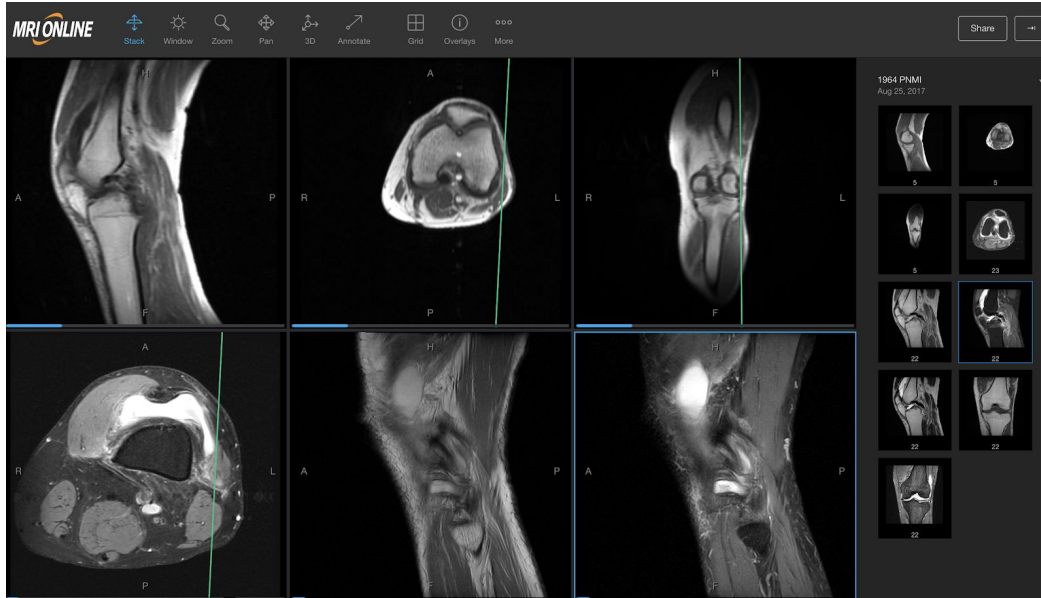


## Proctored Cases

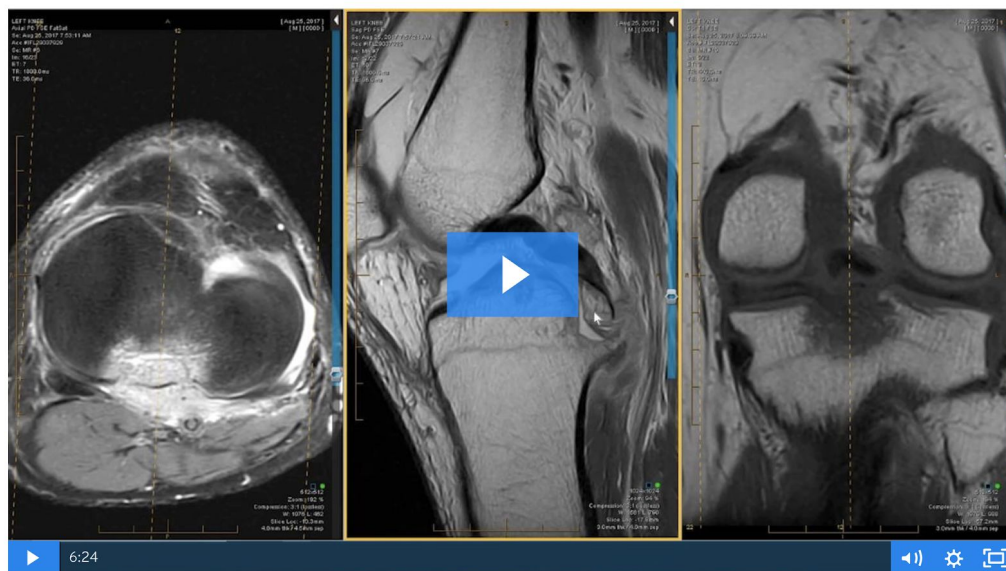
Curated case list of full DICOM cases selected to test your understanding and develop mastery of defined topics. Test your abilities and create your own report to be assessed by our subspecialty radiology proctors



## Interactive Education

Video and text-based supporting educational materials to assist your case interpretations

Case Review: PCL Mechanism of Injury



1. Which of the following meniscal tear locations are least likely to benefit from surgical intervention?

- A. White/white zone
- B. Inner third
- C. Middle third
- D. Outer third
- E. Red/white zone

## 1:1 Feedback

*Line by line review of your reports from an attending radiologist - ask questions to clarify your understanding*

### EDIT TYPE:

Miss:

[Major Miss]

Ancillary or Incidental Findings:

[ ]

[ ] Stylistic changes

[ ] No edit

### REPORT GRADE:

[Does not meet expectations]

### FEEDBACK:

Dominant Finding: Complete acute tear of the pectoralis major tendon, retracted approximately 3.5 cm. A thin irregular pectoralis major stump or falciform ligament extends to deltopectoral groove and is 2 cm long to tears of sternal and probably clavicular head. Intact abdominal head.

Partial-thickness footplate tear anterior insertion supraspinatus tendon measuring 7 x 5 mm, age indeterminate.

Subscapularis tendinosis with peritendinitis, likely chronic.

Moderate adhesive capsulitis, likely chronic.

NB: The orthopedist wants to know where the pectoralis tear has occurred relative to the myotendinous junction; pure myotendinous junction tears are treated non-operatively but ruptures from the humerus or treated operatively.

## Gold-Standard Reports

### Menisci:

Medial Meniscus: Discoid meniscus (Images A-C) with abnormal oblique high signal extending from the body into the posterior horn, extending to part of the superior articular surface (Image D and E). Appearances are consistent with an upper surface (but predominantly closed intrameniscal) flap tear of the discoid meniscus. The tear measures 2-3cm in length from anterior to posterior.

Lateral Meniscus: Intact.

### Ligaments:

Anterior Cruciate Ligament: Complete full-thickness ACL tear. No passive anterior tibial translation.

Posterior Cruciate Ligament: Intact

Medial Collateral Ligament: Diffuse periligamentous edema surrounding the tibial collateral ligament with swelling and increased intrasubstance signal in the proximal tibial collateral ligament, consistent with an intermediate grade/grade 2 injury. Extension anteriorly into a high-grade tear involving the proximal/central medial patellofemoral ligament as described below.

Lateral Collateral Ligament: Subtle periligamentous edema surrounding the fibular collateral ligament, consistent with low-grade/grade 1 sprain. Otherwise unremarkable.

Posterolateral Corner Structures: Intact

Posteromedial Corner Structures: Swollen/edematous, but intact, popliteal oblique and oblique popliteal ligaments. Markedly edematous/swollen posterior meniscocapsular junction suggesting a RAMP 1 injury.

**Extensor Mechanism:**

Patellar Tendon: Intact

Distal Quadriceps Tendon: Intact

Medial Patellofemoral Ligament: High-grade full-thickness tear involving the proximal medial patellofemoral ligament attachment at the adductor tubercle, adjacent to the proximal MCL. The tear extends into the anterior tibial collateral ligament as an intermediate grade injury as described above.

Medial and Lateral Patellar Retinacula: Diffusely edematous lax medial patellar retinaculum. Slightly thickened, tight lateral retinaculum.

Hoffa's Fat Pad: Mild focal superolateral Hoffa's fat pad edema. Otherwise unremarkable.

**Articulations:**

Patellofemoral compartment: No trochlear or patellar dysplasia.

Medial Compartment: Pivot-shift pattern of osseous injury as described below. Otherwise unremarkable

Lateral compartment: Pivot-shift pattern of osseous injury as described below. Otherwise unremarkable.

**General:**

Bones: Subchondral microtrabecular fracture with minimally depressed sulcus terminalis and surrounding lateral femoral condyle high-grade osteoedema. Posterolateral tibial microtrabecular contusion. Posteromedial tibial microtrabecular injury/contusion.

Effusion: Moderate-sized hemoserous suprapatellar effusion with reactive synovitis.

Baker's Cyst: Small partially decompressed Baker's cyst measuring a 2.8 x 1.8 x 0.5 cm with evidence for partial dehiscence. Small amount of extravasated fluid seen tracking superiorly, anterior to the origin of the medial gastrocnemius, between myofascial planes.]

Loose Bodies: None.

Soft Tissues: Unremarkable.

## Case Discussion & Key Images

Discoid Meniscus is an anatomical variation or dysplastic disc shaped meniscus that is prone to injury. It occurs with an incidence of approximately 1-5% and is 10-20 times more common in the lateral meniscus.

Watanabe et al. classifies the lateral discoid menisci into:

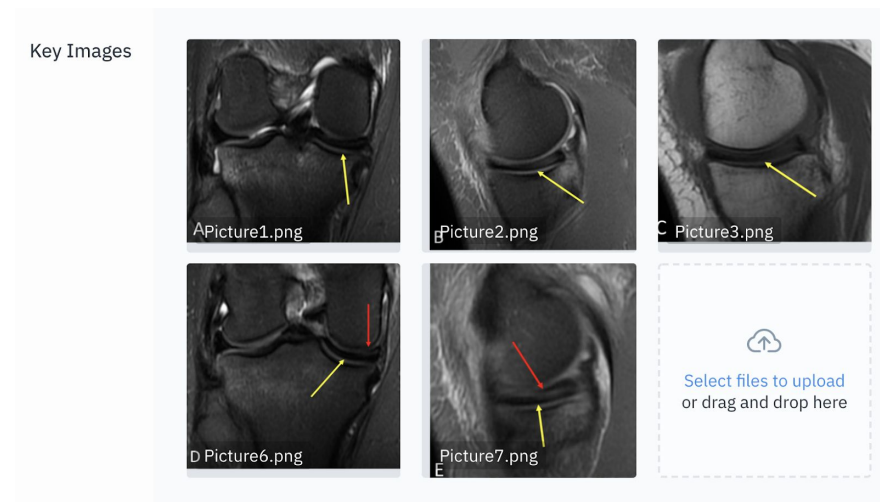
Type I: Complete

Type II: Incomplete

Type III: Wrisberg ligament type (without normal meniscotibial attachments allowing increased mobility and "snapping knee" syndrome).

On MRI, a discoid meniscus is defined as a meniscal body width greater than 15mm in the mid coronal plane or continuity of the meniscus between the anterior and posterior horns over three or more 5-mm-thick contiguous sagittal images.

Possible lateral discoid meniscus associations include: lateral femoral condyle hypoplasia with widened joint space, lateral tibial spine hypoplasia, fibula head dysplasia, ectatic geniculate artery.



Complete discoid meniscus in a 19-year-old with a hyperextension injury 9 days prior, complaining of pain in the popliteal area and severe pain with standing.

A. Coronal PD fat saturated image of the right knee shows a medial meniscus (arrow) that is greater than 15 mm wide in the mid-coronal plane, meeting the criteria for a discoid meniscus.

B. Sagittal PD fat saturated image of the right knee shows a complete discoid shaped medial meniscus, remaining continuous on the third contiguous 5mm thick slice (yellow arrow).

C. Sagittal T1 FSE image of the right knee shows a complete discoid shaped meniscus, remaining continuous on the third contiguous 5mm thick slice (yellow arrow).

D. Coronal PD fat saturated image of the right knee demonstrates a discoid meniscus (yellow arrow) with a small upper surface flap tear (red arrow), illustrating susceptibility to injury of the discoid meniscus.

E. Sagittal PD fat saturated image demonstrates a discoid meniscus (yellow arrow) with a small upper surface flap tear (red arrow).